

Non-surgical treatment for Trigeminal Neuralgia: Research

 caringmedical.com/prolotherapy-news/trigeminal-neuralgia-treatment/

Ross Hauser, MD

The evidence for Trigeminal Neuralgia non-surgical treatments

In our many years of helping people with chronic pain in the head, neck, jaw, and face we have seen many people with a diagnosis of Trigeminal neuralgia. For some of these people, possibly including yourself, it was not easy getting this diagnosis as this problem can be confusing and frustrating to understand. Not only for the patient but the doctor alike.

The importance of the interconnectedness of the cervical spinal nerves and the autonomic nerves and with the cranial nerves, including the trigeminal nerve, cannot be underestimated. Any medical symptom or condition that involves the autonomic nervous system anywhere in the body, but especially the neck, head, and face, could and probably does involve cervical instability. Before a person resolves to the notion that their symptom or medical condition has no known cause and the best they can do is symptom control, cervical instability should be considered as the missing diagnosis.

Here is a story from someone asking for our help. Their email was filled with symptoms.

Diagnosed with trigeminal headaches. I have had a continuous headache for months with a lot of eye pain. The doctor thinks I have eustachian tube dysfunction as well. When the ear fills with fluid I get nauseous. When I go to the ENT the only thing they can come up with is that I have TMJ. The pain in my forehead and eyes becomes worse when driving through to the vibration. I have a past history of a spontaneous cerebral spinal fluid leak. I have not been leaking for many years. I have seen an atlas orthogonal chiro and I have lost the curve in my spine.

Chronic trigeminal neuralgia injection treatment

Ross Hauser, MD discusses chronic trigeminal neuralgia and the types of cases that would typically respond to a treatment like Prolotherapy when the traditional first-line injection treatments are not addressing the underlying structural issue and symptoms continue to return.

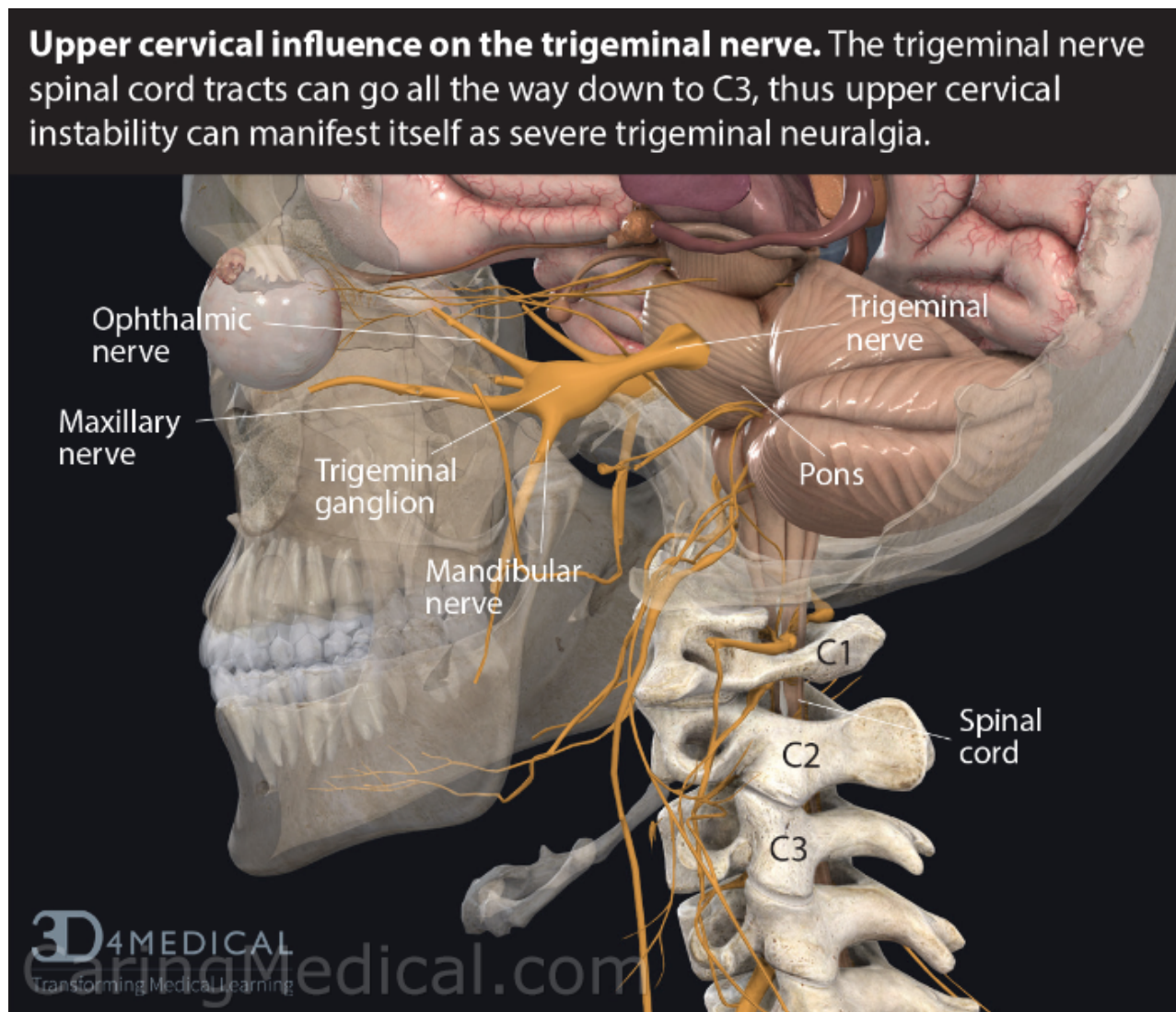
Summary discussions of the video are below:

People who suffer from trigeminal neuralgia know it's one of the worst most painful disabling conditions. At Caring Medical, we see patients in both the acute phase and the chronic phase of trigeminal neuralgia. Most patients, however, we see, who have chronic trigeminal neuralgia, have a long history of the diagnosis. We don't normally see the

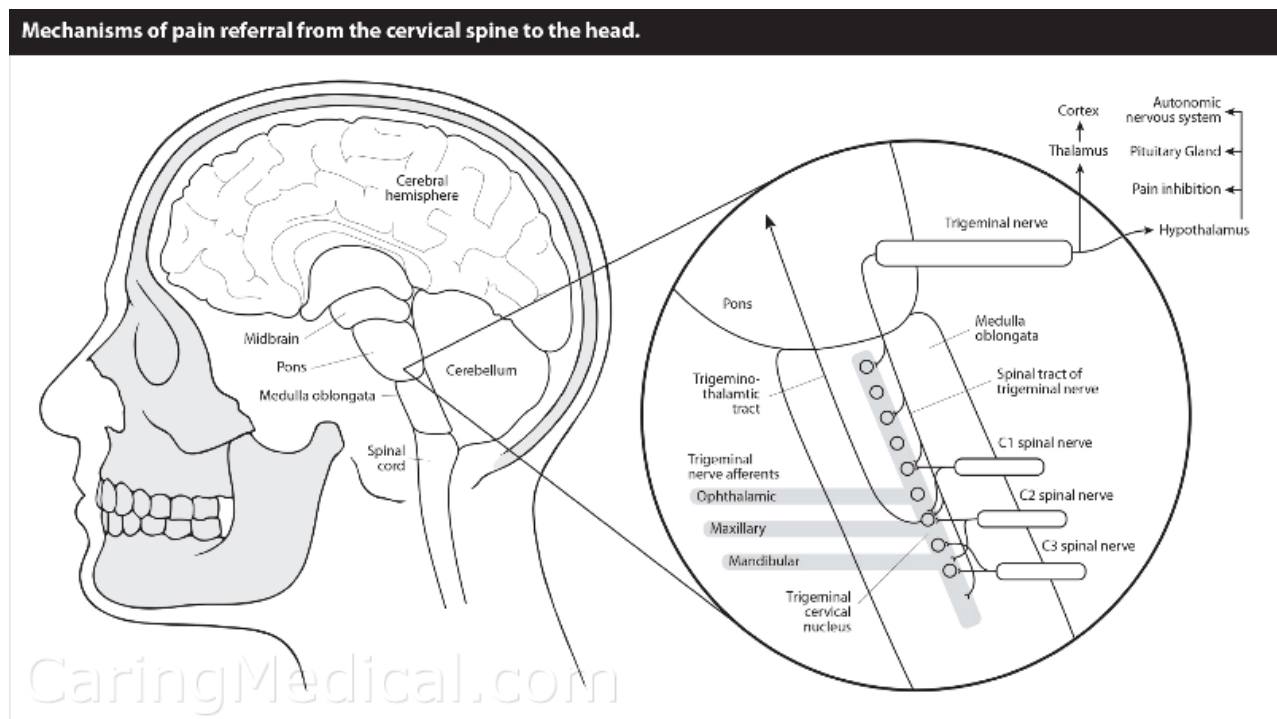
patient when they are first diagnosed with trigeminal neuralgia because of the severity of acute symptoms. Trigeminal neuralgia, because of the uniqueness of the symptoms is easily recognized and gets diagnosed early and correctly. The attending neurologist and primary physician will treat the symptoms with high-dose steroids and then many people will have a resolution of the symptoms or eventually, the person will get referred to an anesthesiologist who will do various nerve blocks. We also offer people nerve blocks. The anesthesiologist will do steroid shots, a nerve block, or radiofrequency ablation. When these standard injection treatments fail to bring long-term resolution of symptoms, people will research other options, find Caring Medical, and reach out to us.

Upper Cervical Influence on the trigeminal nerve. Where do symptoms come from?

In the caption of this image, the trigeminal nerve/spinal cord tracts can reach the C3 level. This indicates that upper cervical spine instability can manifest as severe trigeminal neuralgia.



The trigeminal nerve originates from the pons with this part of the brain stem and then the track goes in the spinal cord all the way down to the C3 level. This is a very important point in understanding the symptoms and pathway of the disorder. The trigeminal cervical nucleus, in other words, the nerve tract for the trigeminal nerve in the spinal cord, because it can descend to the C3 level, this means that upper cervical instability, the wandering, and instability of the cervical vertebrae, can rub, compress, impinge, and irritate the nerve tract for C1, C2, and then those can irritate the trigeminal nerve and you can get symptoms of trigeminal neuralgia.



The example of problems of chewing, cervical neck pain, and upper cervical instability

The trigeminal nerve innervates the muscles of chewing such as the masseter muscles and the pterygoid muscles. When chewing occurs it stimulates the trigeminal nerve. We see many patients who have horrible neck pain with chewing. This can manifest because of upper cervical instability.

Occipital nerve stimulation for recurrent trigeminal neuralgia

A June 2022 paper published in the journal *Neuromodulation* ([10](#)) looked to examine occipital nerve stimulation for recurrent trigeminal neuralgia for the 15% to 30% of patients who will continue to experience intractable pain even following non-surgical and surgical treatments.

The seven patients in this study:

- Average age 49 years old.
- The average pain duration was 8.6 years.

- The average number of medical and surgical treatments before occipital nerve stimulation is five to six.
- A percutaneous trial (implantation of an electric stimulation device) was performed in five of seven patients; all responded with pain relief of more than 40%, and four of five patients experienced pain recurrence after explantation (removal of stimulation device).
- Eventually, six patients had a permanent occipital nerve stimulation implantation.
- All patients reported an improvement after implantation (at an average near five-year follow-up).
- Adverse events were reported for four patients who required surgical revision for lead breakage (1), erosion (1), migration (1), or hardware-related discomfort (1). One patient finally underwent explantation because of infection.

Conclusions: “Although occipital nerve stimulation is not validated in this indication, these results suggest that it can induce an improvement in TN recurring after several surgical treatments, and the benefit of the stimulation can be sustained in the long term.”

Radiofrequency ablation of trigeminal facial pain

A June 2022 study ([11](#)) tested the effectiveness of bupivacaine injection after pulsed radiofrequency ablation in the management of trigeminal facial pain. In this research, a total of 73 patients with trigeminal facial pain who were not responding to conservative therapy were randomized into 2 groups. Group I subjects underwent a pulsed radiofrequency ablation procedure, followed by the injection of 1 ml of bupivacaine. Whereas, Group II underwent the same procedure followed by the injection of 1 ml of normal saline. Pain relief duration, the time of onset of pain relief, and analgesic effect evaluated by a numerical pain rating scale were considered as outcomes.

Results: Thirty-nine patients in Group I and 34 in Group II. The duration of pain relief in the 2 groups was comparable (5 months in Group I vs. 6 months in Group II). The onset of pain relief in the patients of Group I was shorter than in Group II. The application of bupivacaine alone had a significant effect on the reduction of the intake of medications.

Conclusion: In situations involving patients who require rapid pain relief, bupivacaine injection following pulsed radiofrequency ablation can be employed to provide immediate relief without subjecting the patients to the risks associated with major complications.

Percutaneous balloon compression of trigeminal facial pain

Balloon compression is a minimally invasive procedure that can be used to treat trigeminal neuralgia. The treatment seeks to provide pain relief by stimulating or injuring the trigeminal nerve in order to prevent it from transmitting pain signals to the brain.

A June 2022 study in the journal *Pain Practice* ([14](#)) estimated long-term recurrence and complications after percutaneous balloon compression and radiofrequency thermocoagulation of Gasserian (trigeminal) ganglion among a large sample of patients.

In total 1313 patients undergoing percutaneous balloon compression or radiofrequency thermocoagulation for trigeminal neuralgia were assessed for recurrence-free survival. Complications including facial numbness, corneal reflex decrease and masseter weakness were also estimated.

Results:

- For patients who received their first initial percutaneous balloon compression and radiofrequency thermocoagulation, the median recurrence-free survival was 130.1 months and 123.3 months in percutaneous balloon compression and radiofrequency thermocoagulation group with log-rank (a more detailed comparison assessment score).
- The recurrence-free survival rate was:
 - up to 90.6% at 1 year in balloon compression and 91.4% in radiofrequency thermocoagulation.
 - up to 84.6% at 3 years in balloon compression and 83.3% in radiofrequency thermocoagulation.
 - up to 81.5% at 5 years in balloon compression and 78.6% in radiofrequency thermocoagulation.
 - up to 71.5% at 10 years in balloon compression and 64.8% in radiofrequency thermocoagulation.
 - No significant difference was observed in facial numbness degree between the two groups after the procedure. Compared with the percutaneous balloon compression group, ophthalmic complication prevalence was higher in the radiofrequency thermocoagulation group (9.6%). However, masseter weakness incidence was lower (10.7%) than that in the percutaneous balloon compression group (24.0%).

Conclusions: Patients with trigeminal neuralgia seemed to attain similar long-term benefits from percutaneous balloon compression and radiofrequency thermocoagulation, especially in the elderly. However, in order to reduce postoperative complications, percutaneous balloon compression provided a safer alternative for treating trigeminal neuralgia involving ophthalmic division, whereas radiofrequency thermocoagulation could be employed as a preferred regimen for maxillary and mandibular trigeminal neuralgia.

Confusion surrounding Trigeminal Neuralgia is borne out by the definition of trigeminal neuralgia and why surgery would be recommended.

Trigeminal neuralgia means that there is nerve pain in the nerve distribution of the trigeminal nerve. It actually does not tell a person what is causing the condition.

When a physician and a patient believe that a nerve is getting compressed, it is easy to see why surgery would be recommended.

We are going to tackle a few brief learning points about Trigeminal Neuralgia and then we will learn about the treatment options. This article does present an optimistic and realistic opinion for non-surgical treatments.

Trigeminal neuralgia centers on what is happening to the trigeminal nerve which carries pain, feeling, and sensation from the brain to the skin of the face. In the case of trigeminal neuralgia, most medical professionals cannot find the cause for why this pain started. This is borne out by the definition of trigeminal neuralgia. **Trigeminal neuralgia means that there is nerve pain in the nerve distribution of the trigeminal nerve. It actually does not tell a person what is causing the condition.**

- Many people with trigeminal neuralgia initially believed they had a serious problem with their teeth. It could have started one day when they are brushing their teeth and suddenly they had shooting pain in their face/mouth. Some thought they even had an abscess and went to the dentist, the dentist could not find anything.
- For some, the dentist visit caused the trigeminal neuralgia
- The thought of teeth causing the problem is advanced by the fact that the pain a sufferer feels is isolated to one part of the face and is most pronounced in the jaw, teeth, gum, and cheek.

Other related causes

Trigeminal Neuralgia can also be caused by simple daily acts.

- Washing your face, shaving, and the application of makeup.
- Chewing food
- Talking
- Blowing your nose

The problems you were facing and why you are seeking medical care.

Is this you?

- You have a severe toothache-like pain that comes and goes. This pain can last a few seconds or a few minutes.
- This on and off pain can bother you for days or weeks and suddenly go away. Then it can return and the cycle repeats.
- This problem is getting progressively worse.

Why are we examining the neck of a patient who comes in for a Trigeminal Neuralgia consultation?

The keyword is compression. The head and neck, as all parts of the body, live in complex relations. Something in the neck can cause problems in the jaw, face, shoulders, fingers, etc. Problems in the jaw can cause problems in the neck. Any musculoskeletal problem can cause problems of headaches. Back to the keyword compression. We are looking for problems in the neck that can be influencing problems in the head and jaw. When a physician and a patient believe that a nerve is getting compressed, it is easy to see why surgery would be recommended. Unfortunately, when **cervical neck instability** is the cause of neuralgia, the surgery does not help relieve the pain.

Cervical instability can also be responsible for almost all painful neuralgias of the head and face including occipital and trigeminal neuralgia, as well as structural **headaches including tension, migraines, and cluster**. This is not a new concept for us, the examination of the cervical neck area is a crucial component of our comprehensive non-surgical Trigeminal Neuralgia program.

Does nerve compression equal surgery? Microvascular decompression or radiofrequency thermocoagulation

Many sufferers of Trigeminal Neuralgia have been or will be ultimately recommended for a Microvascular decompression surgical procedure. Simply the procedure addresses compression brought on the trigeminal nerve by a vein or artery. In addition to pressing down on the nerve, the flow of blood or pulse through these vessels can cause intermittent stabbing pain which is a key mark of Trigeminal Neuralgia.

A January 2022 paper in the journal *Experimental and Therapeutic Medicine* (**13**) offered this comparison between microvascular decompression and radiofrequency thermocoagulation.

“Although microvascular decompression should be considered as the first-line treatment for classic trigeminal neuralgia owing to neurovascular compression of the trigeminal nerve, an increasing number of surgeons prefer radiofrequency thermocoagulation (heating the nerve) radiofrequency thermocoagulation is a Gasserian (trigeminal) ganglion-level ablative intervention that may achieve immediate pain relief for trigeminal neuralgia. It is used for emergency management when microvascular decompression is not suitable for the patient.”

In comparing the two treatments the researchers write: “there are currently no high-quality controlled trials to evaluate the efficacy of microvascular decompression and radiofrequency thermocoagulation. . .to assess a comparison, the authors examined the effectiveness of the radiofrequency thermocoagulation method in terms of the initial pain relief percentage, recurrence rate and follow-up time.

Radiofrequency thermocoagulation was used for a wider range of applications than microvascular decompression, including use for primary (owing to neurovascular compression of the trigeminal nerve), idiopathic, and secondary (due to primary neurological diseases) trigeminal nerve, and provided a high rate of initial pain relief and long-term pain control. Although this method has several side effects, the incidence of complications could be reduced by precise cannulation. Furthermore, the complications that occurred were not permanent. Thus, radiofrequency thermocoagulation is a safe and effective minimally invasive method of pain relief for patients with trigeminal neuralgia.

Blood vessels compressing the nerve can be corrected without surgery or pharmacological management

Research from university and medical researchers in India published in the October-December 2017 edition of the *Asian Journal of Neurosurgery* reviewed current Trigeminal Neuralgia treatment. **(1)** Here are highlights of their research:

- Trigeminal neuralgia is described as a sudden, severe, brief, stabbing, and recurrent pain within one or more branches of the trigeminal nerve.
Type 1 as intermittent and Type 2 as constant pain represent distinct clinical, pathological, and prognostic entities.
- While there are many things that may cause Trigeminal Neuralgia including nerve compression or nerve stretch injury, neurovascular conflict is the most accepted theory.
 - My comment: Neurovascular conflict is briefly defined as blood vessels compressing upon the nerves, In the description above, nerve compression, nerve stretch injury, and Neurovascular conflict, **can be shown to be problems of cervical neck or jaw joint instability that can be corrected without surgery or pharmacological management.** This will be discussed below.
 - We are going to briefly diverge here to interrupt with a 2006 study that will help us understand this study's suggestion that surgery will no longer be warranted for trigeminal neuralgia. In 2006, Polish researchers wrote in *The Polish Otolaryngology* that:
"Microvascular decompression (MVD) is a treatment of choice, based on the separation of offending (blood) vessel from the nerve. Those procedures are safe, with a high rate of success according to the literature ranging from 70- 90%. **(2)** If the surgery is so good, why not offer it immediately to these patients? The question gets more confused in 2017.

- **Back to 2017 and the Indian research:**

- Carbamazepine (a powerful anticonvulsant medication to treat seizures, nerve pain, and bipolar disorder) is the drug of choice in Trigeminal Neuralgia; baclofen (a muscle relaxant), lamotrigine (to treat seizures, nerve pain, and bipolar disorder), clonazepam (typically for anxiety and panic attacks, whose side effects include an increase in suicidal tendencies), oxcarbazepine (typically to treat epileptic seizures), topiramate (to treat seizures and migraine headaches), phenytoin (for seizures), gabapentin (for seizures and shingles), pregabalin (for nerve and muscle pain, may be offered in cases of fibromyalgia), and sodium valproate (to treat seizures, migraines, and bipolar disorder) can be used.
- Multi drugs are useful when patients are unable to tolerate higher doses of Carbamazepine.
- With the availability of an increasing number of anticonvulsant drugs, it is likely that surgical options may not be offered for many years.¹

The surgical answer? If surgery is so successful, why then subject patients to prolonged drug use as a means to delay the need for surgery?

- Back to the research: “A multidisciplinary approach using **antidepressants and anti-anxiety drugs** such as amitriptyline and duloxetine is needed for the management of emotional status.”¹
- Botulinum toxin Type A injections may be offered to patients before surgery or who are unwilling to undergo surgery, and in failed drug treatment.
- Tetracaine nerve block as an additional treatment after Carbamazepine, acupuncture, and peripheral nerve stimulation can be used.¹

The Indian researchers gave an exhaustive and detailed study on how to help patients with Trigeminal Neuralgia. Like many other conditions we see, surgery is thought to be a good option, but only after years of pharmacological pain management. Why not seek something more curative?

The difficulty in diagnosis and the problems of too much treatment or inappropriate treatment were recently discussed in research by doctors in Germany at the Göttingen University Medical Center. Here they looked at oral problems.

- Trigeminal neuralgia is characterized by repetitive pain commonly triggered by chewing and manipulation of the gums.
- Due to these symptoms, patients are likely to consult their local dentist when symptoms first develop and may receive further dental evaluation and treatment before they are referred to a neurologist or neurosurgeon.
- Forty-one patients (82% of the study group) initially consulted their dentist; of these, 27 patients received invasive dental treatment for the pain syndrome, including extractions, root canal treatments, and implants.

- A high percentage of patients that are surgically treated for trigeminal neuralgia consult their dentist first and **receive possibly unjustified dental treatment**. Differential diagnoses include odontogenic pain syndromes as well as atypical orofacial pain.
- This study acknowledges difficulties in correctly diagnosing trigeminal neuralgia, but seems to underestimate the extent. (3)

The same study looked at the surgical treatment options:

Eighty-two percutaneous rhizotomies (destroying a part of the nerve causing pain) and 33 microvascular decompressions (open brain surgery to relieve pressure on the cranial nerve) were performed in 99 trigeminal neuralgia patients. Two-thirds reported being pain-free in follow-up.

These are very difficult procedures and invasive procedures to get only 2 out of 3 patients pain-free. One out of three continues on with their pain.

In patients over 70 with trigeminal neuralgia

A June 2022 study from the University Hospital of Reims in France (15) examined the effectiveness and complications of microvascular decompression in trigeminal neuralgia patients who were over 70 years old. While suggested that microvascular decompression is a safe and effective technique in the short and long term, the researchers questioned its effectiveness in older patients who are considered more fragile anesthetically and surgically.

- Twenty-five patients, over 70, with trigeminal neuralgia were included. The patients were operated on by the same surgical team.
- Microvascular decompression was found to be “a durable procedure in patients over 70 years of age diagnosed with essential trigeminal neuralgia. The complication rate and immediate-, medium-, and long-term efficacy were similar to those of younger patients.

Trigeminal Neuralgia Is a Dementia Risk Factor

The importance of understanding the treatment of trigeminal neuralgia in the aging patient was demonstrated by a May 2022 study in the *International Journal of Environmental Research and Public Health* (16). The researchers wrote that both dementia and trigeminal neuralgia are most prevalent in females and in patients older than 50 years. Further, recent studies reveal that pain and dementia may have a reciprocal interaction with each other.

In examining whether adults with trigeminal neuralgia have an increased dementia risk, the examined non-trigeminal neuralgia diagnosed patients and compared them to patients with trigeminal neuralgia. They found that the incidence of dementia was higher in the trigeminal neuralgia group compared to the non-trigeminal neuralgia group. “After adjusting for covariates, the trigeminal neuralgia group had a 4.47-fold higher risk of

dementia compared to the non-trigeminal neuralgia group. Additionally, the impact of trigeminal neuralgia on dementia risk was larger in young-aged patients than in old-aged patients. . . trigeminal neuralgia is a dementia risk factor.”

Relapse and recurrence after trigeminal neuralgia surgery

A September 2021 paper published in the journal *Frontiers in Neurology* (4) examined why a group of patients will have a recurrence of primary trigeminal neuralgia following microvascular decompression (MVD) surgery. They also note that previous research as to the actual recurrence rates and the causes of this recurrence “remain controversial.”

- In this paper, the researcher examined seventy-four previously published studies (8,172 patients).
- Overall, 956 out of 8,172 patients relapsed
- Influencing factors of relatively higher recurrence rates included atypical trigeminal neuralgia symptoms, lack of nerve groove, non-arterial compression, patients who were 50-60 years old, and longer disease duration.
- Simultaneously, the recurrence rate of microvascular decompression treatment was much lower than that of conventional drug treatment, gamma knife surgery, percutaneous balloon compression, and radiofrequency thermocoagulation.
- When the surgical technique was improved or combined with partial sensory rhizotomy (heating the nerves), the postoperative recurrence rates were significantly reduced.

Summary conclusion:

Even for primary trigeminal neuralgia patients who have a successful operation, about 10% of them will still relapse.

The research on Neurectomy for trigeminal neuralgia

A neurectomy is considered a nerve block in that it severs the nerve. In some instances, the nerve is removed completely. In March 2019, surgeons discussed neurectomy of the peripheral branches of the trigeminal nerve in the *Journal of Maxillofacial and Oral Surgery*. (5) Here are their findings:

“Oral and maxillofacial surgeons have traditionally employed the peripheral neurectomy in the surgical management of Trigeminal Neuralgia. . . Peripheral neurectomy in trigeminal neuralgia is associated **with a lesser quality of pain relief** in comparison with central neurosurgical procedures. . . Oral and maxillofacial surgeons must not consider the peripheral neurectomy as the first surgical option in the management of classic Trigeminal Neuralgia.”

The research on acupuncture for trigeminal neuralgia

In February 2019, Chinese Medical University researchers looked into the use of acupuncture for Trigeminal Neuralgia. They noted that acupuncture is increasingly used by patients with primary trigeminal neuralgia and that research was limited as to its effectiveness. They published their findings in the journal *Complementary Therapies in Clinical Practice*. (6)

In this study, the researchers examined thirty-three randomized control trial studies. Their analysis demonstrated that the effect of both manual acupuncture and electro-acupuncture for improving response rate and the recurrence rate was **more significant than carbamazepine** (the anticonvulsant drug frequently prescribed for Trigeminal Neuralgia.)

Manual acupuncture achieved a more significant effect on alleviating pain intensity.

However, the Chinese team concluded: that acupuncture might have some positive effects on Trigeminal Neuralgia. Nevertheless, the level of all evidence was low or very low. We could not yet draw a firm conclusion on the efficacy of acupuncture for Trigeminal Neuralgia.

Another new study, however, presented interesting findings in *The Journal of Nervous and Mental Disease*. (7) Here Chinese University hospital researchers made these observations in regard to clinical improvement of cognitive function in patients with Trigeminal Neuralgia following acupuncture treatments.

- The researchers recruited 116 patients with Trigeminal Neuralgia of an undetermined cause.
- The 116 patients were divided into two groups: the acupuncture intervention group and the sham/placebo control group.
- Clinical pain, cognitive function, and quality of life were evaluated at the initial time of treatment, at the end of treatment, and 6 weeks after the treatment.
- Pain intensity, headache, and generalized body pain showed a significant decrease both at the end of treatment and after 6 weeks of treatment when compared with the initial time.
- The scores of the cognitive tests showed significant improvement
- Conclusion: Acupuncture can be used as an alternative treatment to improve cognitive function and quality of life of patients with Trigeminal Neuralgia.

A summary of treatments and a realistic outlook at success and non-successful treatments

In March 2019, in the *European Journal of Neurology* (8) research from an expanded team of European doctors led by the University of Copenhagen and the National Hospital for Neurology & Neurosurgery in London made these recommendations:

- For long-term treatment of Trigeminal Neuralgia, we recommend carbamazepine or oxcarbazepine as a drug of choice.

- Lamotrigine, gabapentin, botulinum toxin type A, pregabalin, baclofen, and phenytoin may be used either alone or as add-on therapy.
- **We recommend that patients should be offered surgery if the pain is not sufficiently controlled medically or if medical treatment is poorly tolerated.**
- Microvascular decompression (to remove herniation or pressure on the trigeminal nerve) is recommended as first-line surgery in patients with classical Trigeminal Neuralgia.
- No recommendation can be given for a choice between any neuroablative treatments (burning out the nerve) or between them and microvascular decompression in patients with idiopathic neuroablative treatments.
- Neuroablative treatments should be the preferred choice if MRI does not demonstrate any neurovascular contact.
- We recommend that patients are offered psychological and nursing support.

In the surgical aspect recommendations, two different types of surgery are offered. One Microvascular decompression is offered when the nerve is being pressed. The Neuroablative is offered when the nerve is not being pressed. At Caring Medical we believe we can present an option away from surgery with Prolotherapy injections because we suspect many patients can be helped non-surgically with Prolotherapy treatments.

Dysfunction of the Trigeminal Nerve

Ross Hauser, MD, and Brian Hutcheson, DC discuss Trigeminal Neuralgia or dysfunction and the strange sensations through the face, throat, and ear. A summary transcript is below the video.

- Trigeminal neuralgia (nerve pain) can be caused by neck problems that lead to instability in the cervical spine, causing irritation of the trigeminal nerve.
- When you have this trigeminal nerve irritation you can get, for lack of a better word, weird swishing, a “creepy-crawlies” sensation in the face, burning in the throat, burning in the inner ear.

Distorted sound sensation

- The trigeminal nerve also innervates (supplies sensation) to the tensor tympani. This is the middle ear muscle that dampens sound.
- Sound Sensitivity with the dampening effect to protect our ears from loud noise or continuous droning background noise.

The connection of the trigeminal nerve to the cervical spine

- There are connections between the upper cervical spine and the trigeminal nerve. There is an afferent or a stimulus that comes in from your upper neck. I have cervical spine instability if you have a terrible problem with loss of the natural curve of the neck. If you have a descending of your brainstem, anything that is a dysfunction can cause a “bad signaling” to come out of the trigeminal nerve.
- **This bad signaling can cause:**
 - Pain in the face.
 - Numbness in your face.
 - Burning ears.
 - Burning in the mouth.
 - Watering of the eyes.

When the trigeminal nerve causes neck pain

Sometimes instead of the cervical spine causing distorted messages to be sent to the trigeminal nerve, the trigeminal nerve can send messages back to the cervical spine that will cause a pain sensation.

- For some people, they can be talking, and then they suddenly develop severe pain in the upper cervical spine.
- Some people can be eating, and then suddenly after the meal, they get a severe headache or cranial pressure or pain in the back of the neck.

Pain in the Face and Mouth

- The trigeminal nerve has three branches:
 - The ophthalmic
 - The maxillary
 - The mandibular
- The trigeminal nerve innervates (supplies sensation) to the face especially the muscles of the face basically the muscles that are involved with chewing, swallowing, and biting.

What is typically underappreciated in patients with pain in the face and the mouth is the association or convergence between sensory nerves of the trigeminal nerve with other cranial nerves and upper cervical nerves (C1-C3).

As discussed, the trigeminal nerve is the fifth cranial nerve (CN V) and is responsible for the sensation in the face and motor functions such as biting and chewing. It is the largest of the cranial nerves and has three major nerve branches: the ophthalmic nerve (V1), the maxillary nerve (V2), and the mandibular nerve (V3).

The sensory function of the trigeminal nerve is to provide tactile (touch), proprioceptive (position), and nociceptive (pain) afferents (sensory nerve impulses) to the face and mouth. It is involved with tearing of the eye as well as secretion production of the nose, sinuses, and other mucosal surfaces. Its motor (muscle) function activates the muscles of chewing and processing food in the mouth: the tensor tympani, tensor veli palatini,

mylohyoid, and the anterior belly of the digastric.

Only the mandibular branch (V3) of the trigeminal nerve has motor fibers. It innervates the muscles of mastication: medial and lateral pterygoids, masseter, and temporalis, as well as the muscles above.

Besides

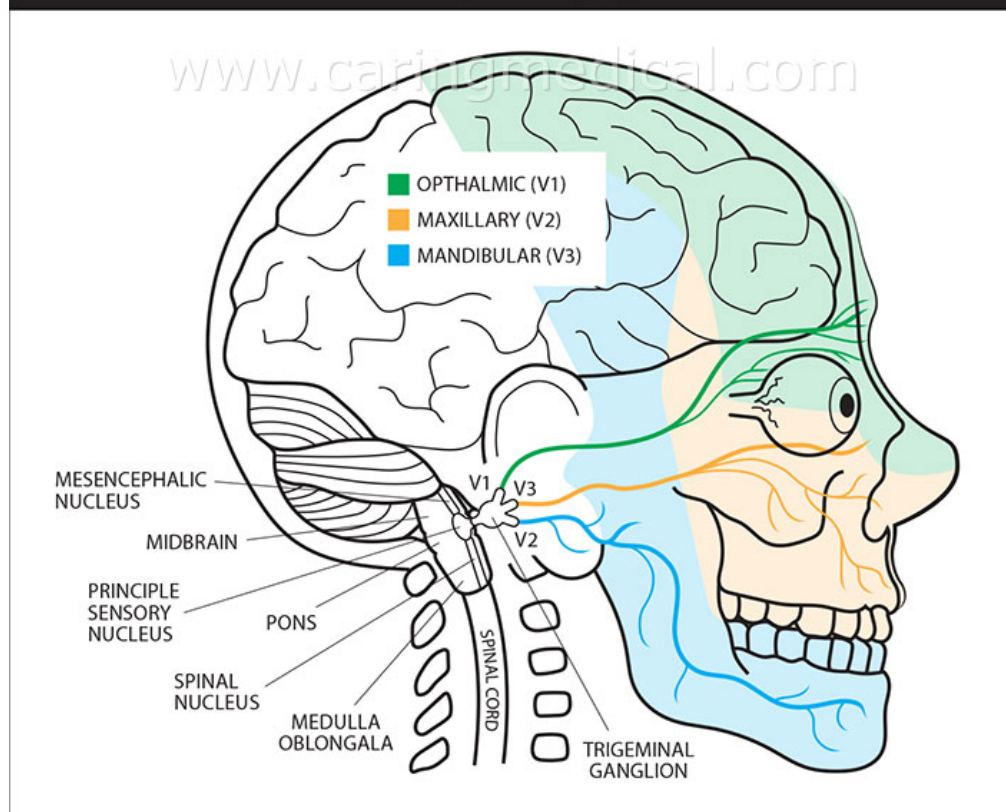
chewing (mastication) some of these muscles are involved in **swallowing** and body balance because of their function in opening and closing the eustachian tube.

The majority of the facial nerve (cranial nerve 7, CN VII) connections involve branches of the trigeminal nerve. These then connect with branches of the vestibulocochlear nerve (CN VIII), the glossopharyngeal nerve (CN IX), and **vagus nerve (CN X)** as well as the branches of the cervical plexus such as the greater auricular, greater and lesser occipital, and transverse cervical nerves. Because of all these connections, the trigeminal nerve receives sensory information from the anterior portions of the head, the greater occipital nerve, and branches of the upper cervical roots in the posterior region.

Cervical disc herniation can cause trigeminal sensory neuropathy by impinging on the spinal trigeminal-cervical nucleus

Nociceptive (painful) sensory information from the trigeminal and upper cervical nerve roots activate neurons in the trigeminal nucleus caudalis, which extends into the upper cervical spinal cord. It also activates neurons in the lateral cervical nucleus in the dorsolateral cervical area as well as neurons in the upper cervical spinal cord. These neurons are multimodal because they receive sensory information from more than one place. Clinically, trigeminal activation produces symptoms in the trigeminal and cervical territory, and cervical activation produces symptoms in the cervical and trigeminal territory. The overlap between the trigeminal and cervical sensory nerve impulses to and from the spinal cord is called convergence. There is definitely an overlap, as even a

The origin of the sensory aspect of the trigeminal nerve. Note that the nuclei are situated within the CNS, and the ganglia outside the CNS.



cervical disc herniation can cause trigeminal sensory neuropathy by impinging on the spinal trigeminal-cervical nucleus. When one understands this, it is easy to see how even chronic tension-type headaches have been found to involve the trigeminal system in their pathophysiology.

Case of trigeminal neuralgia helped with Prolotherapy injections

At this point, we are going to look at **Prolotherapy injections as a treatment option**. Prolotherapy injections are one of the simplest treatments available for **trigeminal neuralgia**. **A simple sugar, dextrose is injected into the jaw area to strengthen the connective tissues of the jaw joint and the cervical vertebrae.**

In cases of trigeminal neuralgia, there is often an undiagnosed ligament laxity either in the neck or the **temporomandibular joint (TMJ)** causing referral pain patterns that create symptoms of trigeminal neuralgia.

In this case:

The patient is a 77 year-old-woman diagnosed with trigeminal neuralgia and as with most people with this pain, no one could determine the cause. She had struggled with this pain for five years.

Previous treatments included six root canals and acupuncture yet her pain remained. A friend referred her to Caring Medical for Prolotherapy.

During the patient's first visit she explained that her greatest pain came with eating, talking, and smiling. Often pain would shoot from her lips to her ears.

Dr. Hauser examined the patient's TMJ and face and determined she would be a good candidate.

Her first treatment consisted of the nerve block to her sphenopalatine ganglion (a group of nerves located in the head, just above the nose) and four dextrose Prolotherapy injections to her left TMJ.

One month later the patient returned and reported that her face was no longer painful to the touch and she no longer had shooting pain from her lips to her ear. She had some pain with talking and eating but was hopeful that the next scheduled treatments would alleviate these problems.

Researching Prolotherapy for Trigeminal Neuralgia

In the *Journal of Prolotherapy*, our colleagues Eileen Conaway, DO and Brian Browning, DO describe a case history of a 63-year-old Hispanic female. (9)

The patient was referred to their office for osteopathic evaluation and treatment for chronic neck and head pain. Among other somatic complaints, her history revealed 13 years of burning pain on the left side of the forehead and scalp.

The pattern of her pain followed the V1 nerve path (see illustration to left). The pain began after undergoing two neurosurgical procedures to repair a cerebral aneurysm.

She reported pain even with a light touch to the affected areas of the scalp and was often unable to brush her hair due to the pain it caused. She had tried over-the-counter analgesics and tramadol-acetaminophen with little relief. She was initially treated with osteopathic manipulation which provided symptomatic relief for a few hours. She was hesitant to try additional medications due to their side effect profile as she also suffered from **hypertension, dyslipidemia, and non-insulin-dependent diabetes.**

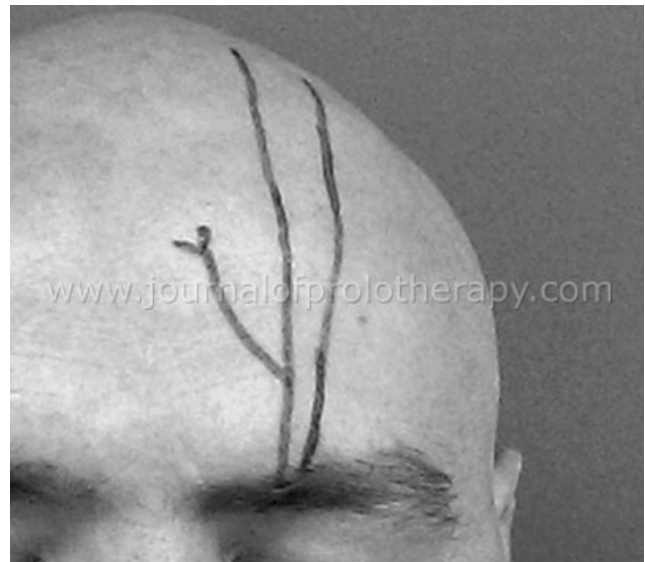

Figure 1. The supraorbital nerve is a branch of the V1 ophthalmic division of the trigeminal cranial nerve (CN V). It passes through the supraorbital foramen to innervate the forehead, extending to the mid-scalp.

She was treated with **Neural Prolotherapy** on three occasions. The first two injections were one week apart, and the third was 12 weeks later.

See the link above: Lyftogt Perineural Injection Treatment™ (also called Neurofascial Prolotherapy, as well as Neural Prolotherapy and Subcutaneous Prolotherapy) is sometimes used side-by-side treatment with traditional dextrose-based **Prolotherapy**. As these techniques work by different mechanisms they can diminish the pain of similar conditions, so they can be given together or separately. In Dextrose base Prolotherapy the ligament and tendon attachments are being treated, in Perineural Injection, the nerves are being treated.

After three treatments with Neural Prolotherapy, she experienced complete resolution of her V1 branch trigeminal neuralgia. After one year, the patient reports the ability to brush her hair without pain and an overall improvement in her quality of life, and her ability to perform activities of daily living.

Also detailed in the *Journal of Prolotherapy* is a case history described by Alan Itkin, PA-C, MS-4 in Treatment of Trigeminal Neuralgia Utilizing Neural Prolotherapy: A Case Report. **(10)**

- A 70-year-old male was referred by his allergist for evaluation and treatment of trigeminal neuralgia.
- The patient reported a history of facial bone fractures nearly 30 years earlier with no subsequent symptoms of trigeminal neuralgia.

- He reported having root canals complicated by infections several years prior to the onset of trigeminal neuralgia.
- His diagnosis of trigeminal neuralgia was made by a neurologist prior to being seen in our clinic.
- At the time of his initial visit, the patient was being treated with carbamazepine and Lamictal.
- The patient complained of severe, sharp, stabbing pains on the right side of his face involving the mandibular, maxillary, and ophthalmic branches of the trigeminal nerve. He also noted severe pain when trying to brush his teeth.

Physical:

Examination showed no focal neurologic deficits. There were dysesthesias (abnormal sensation) and allodynia (abnormal and heightened sense of pain) along the maxillary and ophthalmic branches of the trigeminal nerve.

Throughout the visit, the patient did have a characteristic “tic” every 1-2 minutes due to the pain of trigeminal neuralgia. We elected to proceed with a neural prolotherapy treatment. Prior to the procedure, the patient was given a cotton swab to rub against his gums and teeth to reproduce some of his pain and sensitivity. This was done to obtain a baseline of his pain prior to the procedure.

The patient was treated utilizing a neural prolotherapy technique. Approximately 15 injections were provided to the distribution of the 3 involved branches of the trigeminal nerve.

After the procedure, the patient was instructed to utilize the cotton swab to try and reproduce his symptoms. The patient was unable to reproduce any of the pain and sensitivity that was present prior to the procedure. The patient was observed in the clinic for 15 minutes and had no “tics” from trigeminal neuralgia. The patient was instructed to follow up in 1 week however the patient did not return until 6 months later.

Six-month follow-up:

At this visit, the patient reported that the neural prolotherapy treatment provided him with 5 months of complete resolution of his symptoms. He stated that his symptoms only returned after hitting his head when exiting his car. His complaints at this time involved severe, sharp stabbing pain in the right forehead, right eyeball, periorbital region, and right temple. He complained of pain when getting a haircut, he found that just simply touching his hair and scalp caused him severe pain.

Treatment #2:

The patient was given a second treatment of neural prolotherapy along the course of the trigeminal nerve. The same technique as the first treatment was utilized. The patient again noted an immediate, complete resolution of his pain.

Summary and contact us. Can we help you? How do I know if I’m a good candidate?

We hope you found this article informative and it helped answer many of the questions you may have surrounding Trigeminal Neuralgia. Just like you, we want to make sure you are a good fit for our clinic prior to accepting your case. While our mission is to help as many people with chronic pain as we can, sadly, we cannot accept all cases. We have a multi-step process so our team can really get to know you and your case to ensure that it sounds like you are a good fit for the unique testing and treatments that we offer here.

Please visit the Hauser Neck Center Patient Candidate Form

References for this article:

- 1 Yadav YR, Nishtha Y, Sonjjay P, Vijay P, Shailendra R, Yatin K. Trigeminal neuralgia. *Asian Journal of Neurosurgery*. 2017 Oct;12(4):585. [[Google Scholar](#)]
- 2 Borucki L, Szyfter W, Wrobel M, Sosnowski P. Neurovascular conflicts. *Otolaryngologia polska= The Polish otolaryngology*. 2006;60(6):809-15.[[Google Scholar](#)]
- 3 von Eckardstein KL, Keil M, Rohde V. Unnecessary dental procedures as a consequence of trigeminal neuralgia. *Neurosurg Rev*. 2015 Apr;38(2):355-60; discussion 360. doi: 10.1007/s10143-014-0591-1. Epub 2014 Nov 25.[[Google Scholar](#)]
- 4 Chen F, Niu Y, Meng F, Xu P, Zhang C, Xue Y, Wu S, Wang L. Recurrence Rates After Microvascular Decompression in Patients With Primary Trigeminal Neuralgia and Its Influencing Factors: A Systematic Review and Meta-Analysis Based on 8,172 Surgery Patients. *Frontiers in Neurology*. 2021;12. .[[Google Scholar](#)]
- 5 Yuvaraj V, Krishnan B, Therese BA, Balaji TS. Efficacy of Neurectomy of Peripheral Branches of the Trigeminal Nerve in Trigeminal Neuralgia: A Critical Review of the Literature. *Journal of maxillofacial and oral surgery*. 2019 Mar 1:1-8. [[Google Scholar](#)]
- 6 Hu H, Chen L, Ma R, Gao H, Fang J. Acupuncture for primary trigeminal neuralgia: A systematic review and PRISMA-compliant meta-analysis. *Complementary therapies in clinical practice*. 2018 Dec 24. [[Google Scholar](#)]
- 7 Gao J, Zhao C, Jiang W, Zheng B, He Y. Effect of Acupuncture on Cognitive Function and Quality of Life in Patients With Idiopathic Trigeminal Neuralgia. *The Journal of nervous and mental disease*. 2019 Jan. [[Google Scholar](#)]
8. Bendtsen L, Zakrzewska JM, Abbott J, Braschinsky M, Di Stefano G, Donnet A, Eide PK, Leal PRL, Maarbjerg S, May A, Nurmikko T, Obermann M, Jensen TS, Cruccu G. EAN guideline on trigeminal neuralgia. *Eur J Neurol*. 2019 Mar 12. doi:10.1111/ene.13950. [Epub ahead of print] PubMed PMID: 30860637.
- 9 Conaway E, Browning B, Neural Prolotherapy for Neuralgia. *Journal of Prolotherapy*. 2014;6:e928-e931.
- 10 Itkin A. Treatment of Trigeminal Neuralgia Utilizing Neural Prolotherapy: A Case Report. *Journal of Prolotherapy*. 2016;8:e961-e965.
- 11 Balossier A, Donnet A, Régis J, Leplus A, Lantéri-Minet M, Fontaine D. Occipital Nerve Stimulation for Recurrent Trigeminal Neuralgia Without Occipital Pain. *Neuromodulation: Technology at the Neural Interface*. 2022 Jun 7. [[Google Scholar](#)]
- 12 Hilal FM, Alyamani OA, Kaki AM. Efficacy of bupivacaine injection after pulsed radiofrequency ablation in the management of trigeminal facial pain: A prospective, randomized, and double-blind study. *Saudi Med J*. 2022 Jun;43(6):551-558. doi:

10.15537/smj.2022.43.6.20220089. PMID: 35675940.

13 Wang Z, Wang Z, Li K, Su X, Du C, Tian Y. Radiofrequency thermocoagulation for the treatment of trigeminal neuralgia. *Experimental and Therapeutic Medicine*. 2022 Jan 1;23(1):1-1. [[Google Scholar](#)]

14 Zheng S, Yuan R, Ni J, Liu H, Yang Y, Zhang S, Li J. Long-term Recurrence-free Survival and Complications of Percutaneous Balloon Compression and Radiofrequency Thermocoagulation of Gasserian Ganglion for Trigeminal Neuralgia: A Retrospective Study of 1313 Cases. *Pain Practice*. 2022 Apr 23. [[Google Scholar](#)]

15 Domages C, Brenet E, Labrousse M, Bazin A, Chays A, Kleiber JC, Dubernard X. Efficacy and complications of microvascular decompression in patients over 70 years with trigeminal neuralgia. *Acta Neurologica Belgica*. 2022 Mar 30:1-9. [[Google Scholar](#)]

16 Cheng YH, Wu CH, Wang WT, Lu YY, Wu MK. Trigeminal Neuralgia Is a Dementia Risk Factor: A Retrospective Cohort Study. *International Journal of Environmental Research and Public Health*. 2022 May 17;19(10):6073. [[Google Scholar](#)]

This article was updated June 14, 2022

6465